

Case report:

External Cervical Resorption Review and a Case Report Type of Manuscript: Case report

Dr.Anubhuti¹ · Dr.Rahul Maria² · Dr.Pankaj Mishra³

Institute/college: Rishiraj College of Dental Sciences And Research Centre , Bhopal, Madhya Pradesh 462036

Corresponding author : Dr.Anubhuti

Abstract

Invasive cervical resorption is a type of external resorption that begins below the epithelial attachment. The etiology of invasive cervical resorption is mainly caused by trauma and orthodontic treatment. It has been a quandary from the standpoints of both its diagnosis and treatment. It is characterized by its cervical location and invasive nature, this resorptive process leads to progressive and usually destructive loss of tooth structure. This resorption of cervical enamel and dentin is asymptomatic and often noticed unexpectedly on routine radiographs or upon clinical examination and is depicted by a pink spot in the crown overlying the highly vascular resorptive tissue. This case report presents the treatment and follow-up of a maxillary central incisor with cervical external root resorption.

Introduction

Invasive cervical resorption is a relatively uncommon form of external root resorption which has been a source of interest and academic debate by clinicians and researchers for over a century¹

Dental Resorption constitutes a challenge to dentistry due to the organic complexity of the process² The condition of Idiopathic Cervical Resorption was first studied by ‘Mueller and Rony’ in 1930. The terminology Invasive Cervical Resorption was used by ‘Heithersay’ in 1999.⁷

It is defined as ‘a localized resorptive process that commences on the surface of root below the epithelial attachment and the coronal aspect of the supporting alveolar process, namely the zone of the connective tissue attachment’ Resorption of coronal dentin and enamel often creates a clinically obvious pinkish color in the tooth crown as highly vascular resorptive tissue becomes visible through thin residual enamel¹ .Once diagnosed, treatment should immediately follow since it can lead to extensive loss of tooth structure as it progresses.³

An external root resorption mainly occurs when the protective pre cementum layer is mechanically damaged or removed which allows for the denuded areas of the root surface to be colonized by clastic cells and for the resorption to get progressively worse. An external invasive cervical resorption (EICR) is a type of external resorption that is unusual and very aggressive.⁴

Etiology:

The aetiology of both idiopathic internal and external root resorption remains elusive.⁷ There are several predisposing factors that are related to the injuries from resorption, orthodontic movement, dentoalveolar surgery, orthognathicsurgery, periodontal treatment and tooth whitening procedures, alone or combined.

Clinical and radiographic features

This kind of resorption usually develops very slowly and it is initially asymptomatic and is sometimes found in a routine radiographic examination. Although early diagnosis can be difficult, some clinical signs may suggest the

presence of resorptive process, such as a rosacealike discoloration of the tooth, discrete contour irregularities with or without gingival bleeding on probing, and in more advanced cases, the adjacent periodontium presenting edema due to secondary infection. The radiograph may show a radiolucent area in the demarcated root structure by a thin radioopaque line that matches the outlines of the canal area overlapping the irregular external resorption which may be associated with a slight irregularity in the adjacent bone crest. The progression of EICR starts from a small point of entry of granulomatous tissue in the cervical area towards the apical or crown portion. The extent of the resorptive defect inside the tooth can be used to classify the lesions from levels 1 to 4⁴

A clinical classification has been developed as a clinical guide in the assessment of cases of invasive cervical resorption. Heithersay G.S has proposed a clinical classification of invasive cervical resorption depending on the amount of destruction.¹ (Table 1)

Table 1: Clinical Classification of Invasive Cervical Resorption	
Class 1	Denotes a small invasive resorptive lesion near the cervical area with shallow penetration into dentine.
Class 2	Denotes a well-defined invasive resorptive lesion that has penetrated close to the coronal pulp chamber but shows little or no extension into the radicular dentine
Class 3	Denotes a deeper invasion of dentine by resorbing tissue, not only involving the coronal dentine but also extending into the coronal third of the root
Class 4	Denotes a large invasive resorptive process that has extended beyond the coronal third of the root

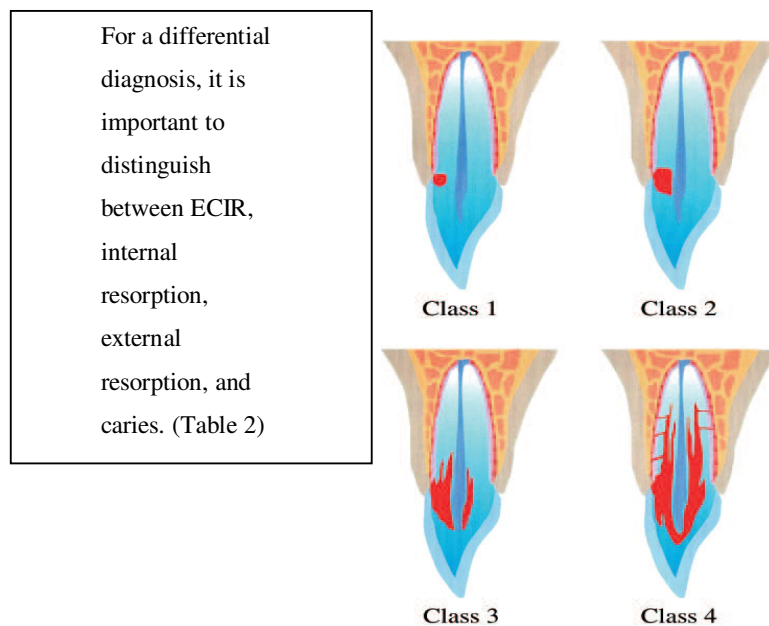


Fig 1: Clinical classification of invasive cervical resorption.

	Table 2: Differences between ECIR, internal resorption, root caries, and external resorption.			
	<i>Road map</i>	<i>Internal resorption</i>	<i>Root caries</i>	<i>External resorption</i>
PROGRESSION	Outside-In	Inside-Out	Outside-In	Outside-In
PULP STATUS	Generally vital	Vital	Vital or Necrotic	Necrotic
RADIOGRAPHIC APPEARANCE	Irregular, variable density	Symmetrical, smooth margins	Symmetrical	Asymmetrical, moth-eaten
	Hyper calcified around canal	Canal outline enlarged	Canal outline visible	Canal outline visible
PROBING	Hard, smooth, knife-edged	Usually not probeable	Soft, decalcified Variable	Variable

TREATMENT PLAN:

Treatment depends on the severity, location, whether the defect has perforated the root canal system, and the restorability of the tooth.

Several treatment regimens have been suggested in the literature, depending on the nature of the ECR lesion, and are usually based on isolated case reports. These include intentional replantation, guided tissue regeneration, treating the ECR lesion by an internal approach only like MTA/Bio dentine placement in resorbed area and forced orthodontic eruption.

Table 3: Treatment Objectives to be Considered When Managing ECR
Arrest resorptive process Restore damaged root surface Prevent further resorption Improve esthetics of tooth (in cases where resorption has led to a pink spot)

This case report demonstrates a clinical outcome of a maxillary central incisor with external cervical resorption.

Case presentation:

A 47-year-old male patient reported with a chief complaint of pinkish discoloration from upper front tooth region since last 2 months. He gave past history of restoration in the same region on clinical examination gingival recession and restoration seen in relation to 11 and 21. (Fig 2) probing revealed pocket depth of 2mm.vitality was done. The pulp of adjacent and contra lateral teeth reacted normally to thermal and electric test whereas 11 was non-vital. A decision to endodontically treat 11 and the resorptive defects with MTA and simultaneously do scaling and curettage was made, treatment plan was explained to the patient and informed consent was taken.in tooth 11 access opening was done, canals was cleaned and shaped using stainless steel hand files, irrigated with 3 % NaOCl and CHX as the final irrigant. Canal was filled with Calcium hydroxide and sealed with cavit and patient was recalled advised 2%CHX mouth wash. Patient was recalled after 2 weeks for obturation. In between oral prophylaxis and curettage was done. After 2 weeks recall canal was cleaned and obturation just below the resorptive defect. The resorptive defect was filled with MTA, the excess was removed and defect was closed with composite. (Fig 4) The patient was instructed to maintain oral hygiene. Follow up showed favourable healing.

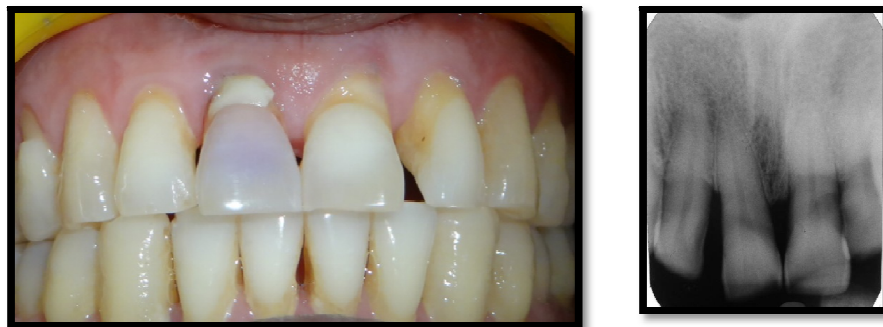

Figure 2. Pre-operative photograph and IOPA

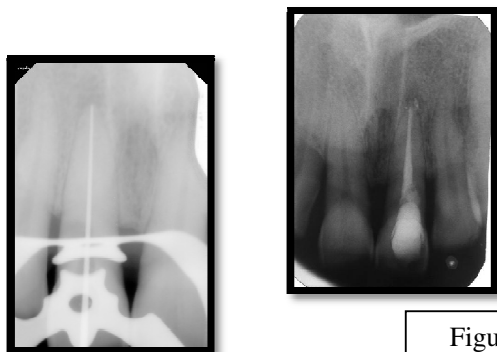


Figure 3: working length determined and resorptive area filled with MTA

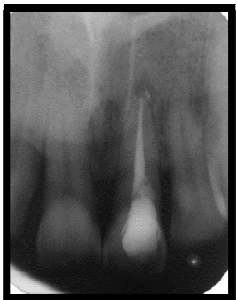

Figure 4: 3 months follow-up radiograph of the tooth

Discussion:

Tooth resorption is a pathologic condition that still remains a mystery in many aspects. It may go unnoticed over many years as most cases of resorption are asymptomatic in nature. Early detection of resorption is essential for successful management. At the first stage, the resorptive process does not penetrate the pulp space because of the protective layer of pre dentin, but rather spreads around the root in an irregular fashion.³

With time, the progress may penetrate into the root canal. Additionally, periodontal infection resorption will include the alveolar bone adjacent to the resorption will include the alveolar bone adjacent to the resorption lacunae in the tooth. If the resorptive process reaches a supra gingival area of the crown, the vascularized granulation tissue of the resorption lacuna may be visible through the enamel showing pink discoloration at the crown.

The basic aim of treating invasive cervical resorption is the complete removal of resorptive tissue and the restoration of the defect area. Unless proper treatment is initiated, this type of resorption continues and a large irreversible loss of tooth structure may appear with time.³ Root canal treatment and management of the resorption were performed in one session in order to avoid secondary infection. Mineral trioxide aggregate was chosen as the filling material for its biocompatibility and for its sealing ability. Although this case report presents a favorable outcome, further studies are encouraged to support the use of MTA to fill external invasive cervical resorption.⁴

Root canal treatment and management of the resorption were performed in one session in order to avoid secondary infection. Mineral trioxide aggregate was chosen as the filling material for its biocompatibility and for its sealing ability. Although this case report presents a favorable outcome, further studies are encouraged to support the use of MTA to fill external invasive cervical resorption.⁴

Conclusion:

Early detection is essential for successful management and outcome of ECR. Patients with a history of 1 or more predisposing factors should be monitored closely for initial signs of ECR. In conclusion, the quote from Dr. Henry Rankow gives the best explanation of the predicament presented for the clinical management of this lesion, "ECR is an 'outside-in' problem that is very difficult to treat 'inside-out'".¹⁰

References

1. Geoffrey s. Heithersay, Endodontic Topics 2004, 7, 73–92
2. Shilpa D Kandalganekar et.al, Journal of International Oral Health. Nov-Dec 2013; 5(6):124-30 [124]
3. Ahmed Kulsoom Siddiqui et.al, Journal of interdisciplinary Dentistry /may-aug 2013/vol-3/issue-2
4. Luiz Fernando Machado Silveira, Carina Folgearini Silveira, Josué Martos, Edno Moacir Piovesan, and João Batista Cesar. Clinical technique for invasive cervical root resorption. J Conserv Dent. 2011 OctDec;14 (4): 440–444.
5. Anuja Ikhari et.al Management of External Invasive Cervical Resorption Tooth with Mineral Trioxide Aggregate: A Case Report, Case Reports in Medicine Volume 2013, Article ID 139801, 5 pages
6. Mitchell H. Davich Treating External Cervical Invasive Resorption, Endodontic therapy vol. 7 no. 2
7. H Liang EJ Burkes and NL Frederiksen, Multiple idiopathic cervical root resorption: systematic review and report of four cases, Dentomaxillofacial Radiology (2003) 32, 150–155

8. Zohreh Ahangari et al, Interventions for the management of external root resorption, Cochrane Database of Systematic Reviews 2010, Issue 6.
9. Shanon Patel, Shalini Kanagasingam, and Thomas Pitt Ford External Cervical Resorption: A Review, JOE — Volume 35, Number 5, May 2009
10. Bergmans L, Van Cleynenbreugel J, Verbeken E, Wevers M, Van Meerbeek B, Lambrechts P. Cervical external root resorption in vital teeth, J Clin Periodontol 2002; 29: 580–585
11. Dimitris Nikolidakis et al Cervical external root resorption: 3-year follow-up of a case, Journal of Oral Science, Vol. 50, No. 4, 487-491, 2008
12. Nizar Ahmed, J Nat , External cervical resorption case report and a brief review of literature, Sci Biol Med. 2014 JanJun; 5(1): 210–214.
13. Bruno Oliveira de Aguiar Santos et al, Root resorption after dental traumas: classification and clinical, radiographic and histologic aspects, RSBO. 2011 Oct-Dec; 8(4): 439-45
14. Luiz Fernando Machado Silveira et al, Clinical technique for invasive cervical root resorption J Conserv Dent. 2011 Oct-Dec; 14(4): 440–444.
15. Robia Ghafoor, Conservative management of progressive external inflammatory root resorption after traumatic tooth intrusion, J Conserv Dent. 2013 MayJun; 16(3): 265–268.
16. Senem Yigit Ozer, Diagnosis and Treatment Modalities of Internal and External Cervical Root Resorptions: Review of the Literature with Case Reports, Int Dent Res 2011; 1: 32-37
17. Patel et al , External Cervical Resorption: A Review, J Shanon OE — Volume 35, Number 5, May 2009